

Case Reports

Third Ventricular and Interpeduncular Fossa Tubercular Abscess With Triventriculomegaly - Ventriculoscopic Surgical Management

FORHAD HOSSAIN CHOWDHURY,¹ MD. RAZIUL HAQUE,² MD SARWAR MORSHED ALAM³

Abstract:

Intracranial tuberculomas are rather common lesions in developing world. Tuberculomas are usually located in cerebellum, basal ganglia and cerebral hemispheres, particularly in frontoparietal region. Less common sites include the corpus callosum, quadrigeminal plate, the cerebellopontine angle, the retro-orbital region, the anterior optic pathway and the suprasellar region. The central nervous system (CNS) involvement comprises approximately 10–15% of all tuberculous infections. Brain tuberculosis is usually parenchymal. Intraventricular tuberculosis is very rare and only little number of cases has been reported. Intraventricular tubercular abscess is further rarer. Here we report a case of third ventricular tubercular abscess with triventriculomegaly that was managed by ventriculoscopic drainage and third ventriculostomy though preoperative diagnosis & surgical planning was different.

Keywords: Third ventricular., Tubercular abscess, Ventriculoscopic surgical management

Introduction:

Intracranial tuberculomas are rather common lesions in developing world.⁶ In India, 20% of all intracranial space occupying lesions are tuberculomas.³ Tuberculomas are usually located in cerebellum, basal ganglia and cerebral hemispheres, particularly in frontoparietal region.³ Less common sites include the corpus callosum, quadrigeminal plate, the cerebellopontine angle, the retro-orbital region, the anterior optic pathway and the suprasellar region.³ The central nervous system (CNS) involvement comprises approximately 10–15% of all tuberculous infections.⁸ Ventricular involvement in neurotuberculosis can occur in different ways. Juxta ependymal focus of Rich causes meningitis by rupturing into the subarachnoid spaces. It may also cause variable degree of inflammation of the ependyma of the ventricular surface and the choroid plexus with formation of tubercle, tuberculoma and rarely abscess. Well formed intraventricular tuberculoma is extremely rare and only a few cases have been recorded. However, intraventricular tubercular abscess has rarely been reported.⁹

Here we report a case of third ventricular tubercular abscess with triventriculomegaly that was managed by ventriculoscopic drainage and third ventriculostomy though preoperative diagnosis & surgical planning was different.

Case presentation:

An 18 years old girl presented with headache, vomiting, visual disturbance, imbalance in walking. There was no history of convulsion, unconsciousness, menstrual or endocrine disturbance. She was drowsy but easily arose able. Her higher psychic functions including memory were normal. There was bilateral papilloedema. Visual acuity and field of vision were normal. Other neurological examinations including cranial nerves revealed no abnormality except imbalance during walking. Other systemic examination revealed no abnormality. MRI of brain showed a 1.5x1x0.5 cm hyperintense mass (that did not enhanced further after

1. Neurosurgeon, Dept. of Neurosurgery, Dhaka Medical college Hospital, Dhaka.
2. Associate professor, Dept. of Neurosurgery, Dhaka Medical college Hospital, Dhaka.
3. Dept. of Neurosurgery, Dhaka Medical college Hospital, Dhaka.

Correspondence: Dr. Forhad Hossain Chowdhury, FCPS; Neurosurgeon, Dept. of Neurosurgery, Dhaka Medical college Hospital, Dhaka, Bangladesh. Phone +8801711949570, e-mail-forhadchowdhury74@yahoo.com

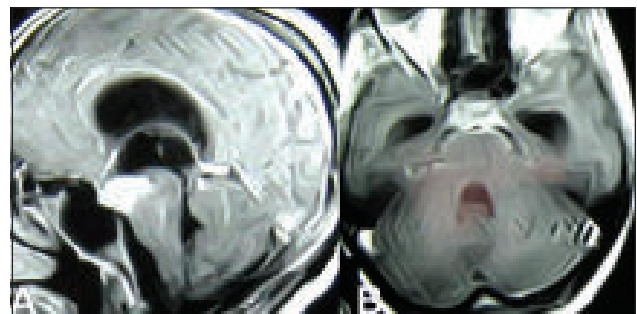

Fig.-1 : MRI of brain A-sagittal view, B-axial view showing tuberculus lesion in the floor of third ventricle.

contrast injection) in the floor of third ventricle with triventriculomegaly (Figure 1A&B). The lesion was approached for biopsy by neuro-endoscope through right sided Kocher's burr hole with the hope to put a ventriculo-peritoneal shunt through this hole. During biopsy taking pus and caseous material came out (Figure 2A,B,C,D,E,F). The pus and caseous material was removed & washout. Finally it was possible to make a ventriculostomy at the floor of third ventricle safely. Histopathology report was tuberculosis and she was put on anti-TB. She recovered slowly. Her neurological examination revealed no abnormality at the end of 06 months after operation. Post operative MRI showed no residual lesion at the end of 18 months.

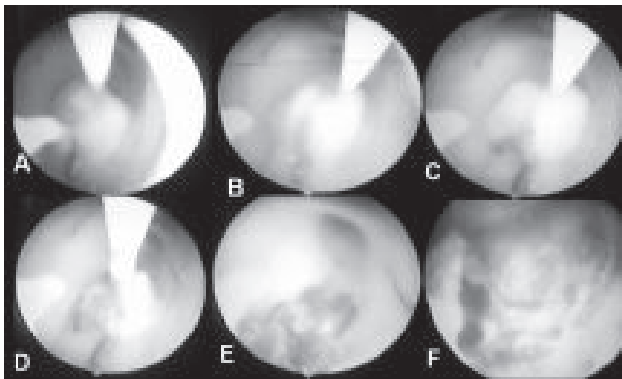


Fig.-2: A,B,C & D-per-operative endoscopic view of lesion in the floor of third ventricle during partial excision. E&F-peroperative endoscopic view of lesion after partial excision.

Discussion

Tuberculosis involving CNS is a serious condition with mortality and morbidity especially in developing countries. There is also resurgence in developed countries due to human immunodeficiency virus (HIV), immigration and development of multi-drug resistant strains.⁶ Central nervous system tuberculosis may appear as tuberculous meningitis, tuberculoma, abscess or Pott's disease.⁴ Tuberculomas account for 10-30% of all intracranial masses in developing countries, and 0.5-2% in developed countries.² Common sites for tuberculomas are cerebral hemispheres and basal ganglia in adults, and in cerebellar hemispheres in children, due to the large blood supply to these areas.⁶

Patients generally present with the complaints of ptosis, headache, and diplopia. Neurological examination reveals involvement of the cranial nerves contained within the cavernous sinus. Simultaneous involvement of other system is not common.¹ There are no pathognomonic radiological findings for a tuberculoma,¹ so confirmation is only possible by histopathological study or by isolation of bacteria from

the lesion. A necrotic caseous center surrounded by a capsule composed of fibroblasts, epithelioid cells, Langhans giant cells and lymphocytes is the picture of a tubercle under the microscope.⁶

Here surgery is needed to establish a diagnosis and to exclude other possibilities (i.e. meningioma, lymphoma, metastasis). In our case we went for surgery to confirm diagnosis along with the hope for improvement of ptosis and 3rd nerve functions. We only excised the tuberculoma in the cavernous sinus leaving the other tuberculomas in situ. Complete excision is not always necessary in tuberculomas in CNS.⁷ Though mainstay of treatment in intracranial tuberculomas is medical⁷ but diagnosis is usually made after a surgical intervention. Overall mortality is 10%.⁵

Conclusion:

In brain and skull base lesions one must not forget the possibility of tuberculosis which is a curable disease with appropriate surgical and medical management.

Conflict of Interest : None

References:

1. Al Soub H, Al Alousi FS, Al-Khal AL. Tuberculoma of the cavernous sinus. *Scand J Infect Dis* 2001; 33: 868-870.
2. Artico M, De Caro GM, Carloia S, Salvati M, D'Ambrosio M, Delfini R. Advances in diagnosis, treatment, and prognosis of intracerebral tuberculomas in the last 50 years: Report of 21 cases. *Neurochirurgie* 1999; 45:129-133.
3. Berthier M, Sierra J, Leiguarda R. Intraventricular tuberculoma. Report of four cases in children. *Neuroradiology* 1987; 29:163-167.
4. Gropper MR, Schulder M, Sharan AD, Cho ES. Central nervous system tuberculosis: Medical management and surgical indications. *Surg Neurol* 1995; 44:378-385.
5. Gupta RK, Jena A, Singh AK, Sharma A, Puri V, Gupta M. Role of magnetic resonance (MR) in the diagnosis and management of intracranial tuberculomas. *Clin Radiol* 1990; 41: 120-127.
6. Hua SE, Clatterbuck RE, Stern BJ, Sampath P, Rhines LD. Sarcoidosis, tuberculosis, and xanthogranuloma In: Winn HR, editor. *Youmans Neurological Surgery*, Vol 1. Philadelphia: Saunders 2004:1435-1447.
7. M. Bozbuga, B.O. Boran & C. Bayindir : Tuberculoma Of The Cavernous Sinus . *The Internet Journal of Neurosurgery*. 2005 Volume 2 Number 2
8. Prabhakar S, Thussu A. Central nervous system tuberculosis. *Neurol India* 1997; 45(3): 132-40.
9. Vajramani GV, Devi BI, Hegde T, Santosh V, Khanna N, Vasudev MK. Intraventricular tuberculous abscess: a case report. *Neurol India* 1999; 47:327